

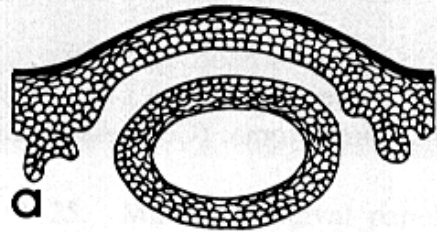
Extraoral Masses



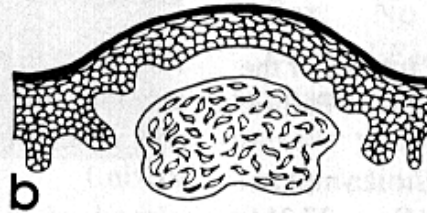
Extraoral Tumefactions

- Unilateral Salivary Swellings
- Bilateral Salivary Swellings
- Lateral Neck Masses
- Midline Neck Masses
- Diffuse Facial Swellings
- Focal Facial Swellings

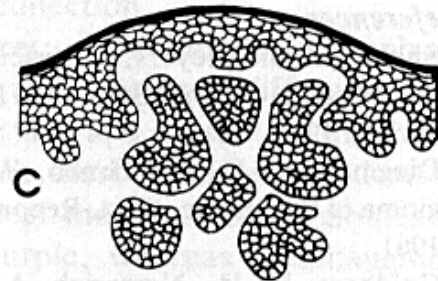




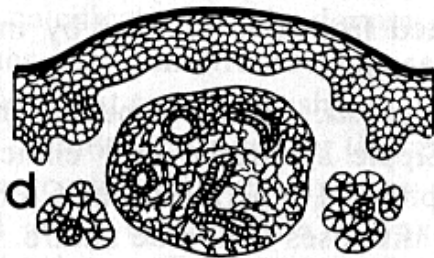
Cyst



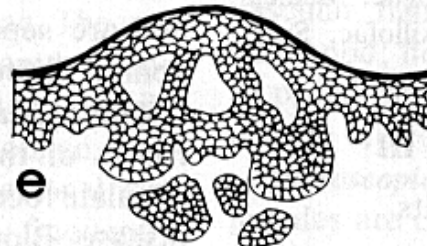
Mesenchymal neoplasm



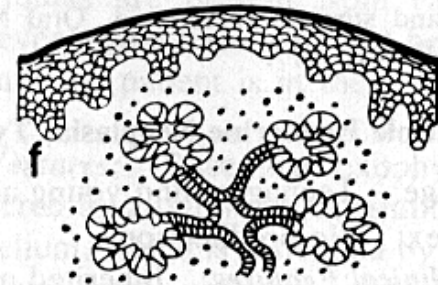
Adnexal skin tumor



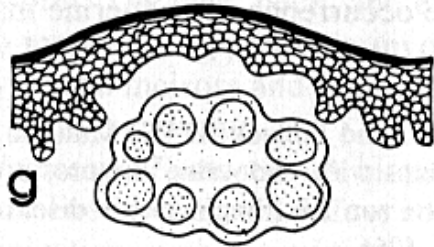
Glandular neoplasm



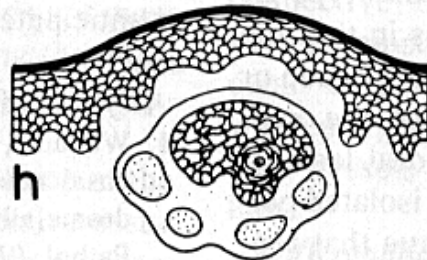
Epithelial neoplasm



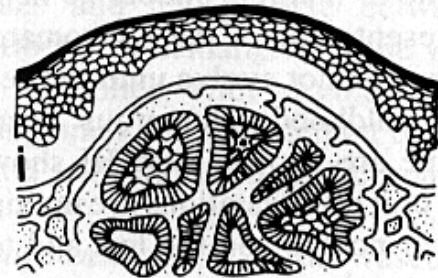
Sialadenitis



Lymphadenitis



Lymph node metastasis



Expansile osseous neoplasm

Extraoral Swellings

