



Radio-opaque Lesions of the Jaws

R



Opaque Patterns

- Focal Periapical Opacities
- Multifocal and Confluent Opacities
- Inter-radicular Target Lesions
- Pericoronal Target Lesions
- Ground Glass Opacities
- Cortical Redundancies
- Intrasinus Opacities



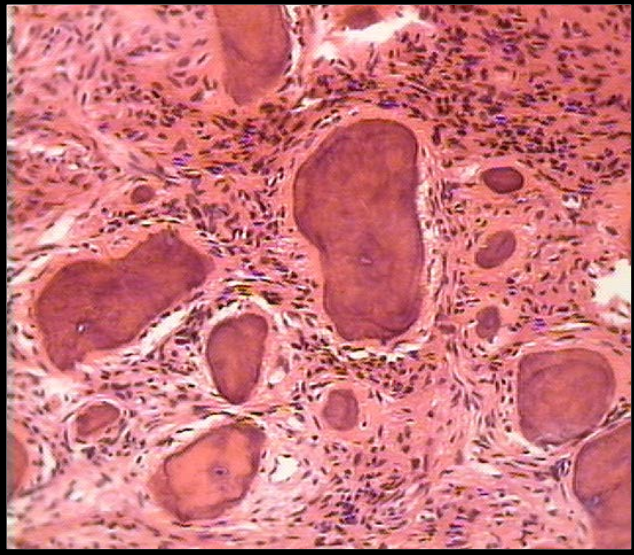
Microscopic Causes of Opacity

- Bone
- Calcified Cartilage
- Enamel
- Dentin
- Cementum
- Foreign Bodies
- Sialoliths
- Phleboliths
- Dystrophic Calcifications

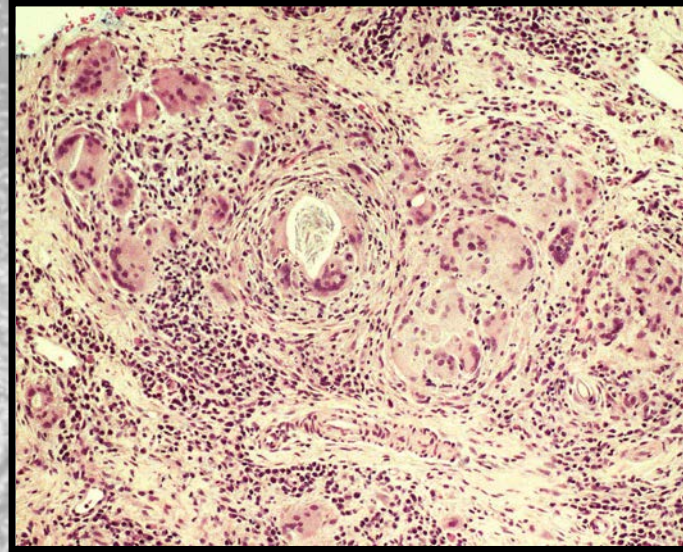


Histology of Opacification

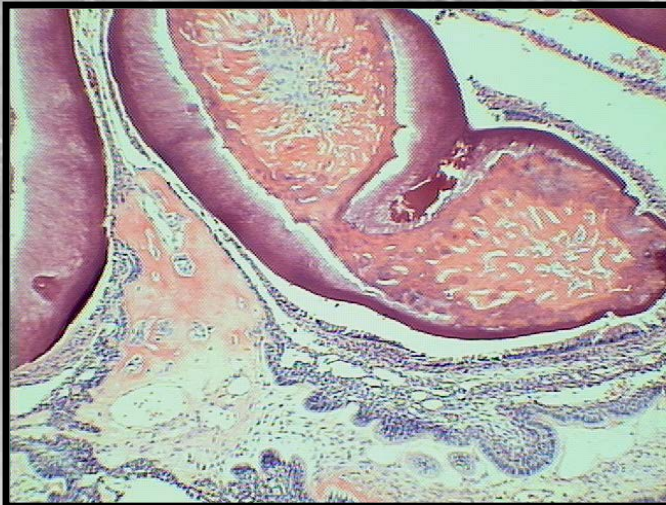- Osseous Tissues



- Foreign Objects



- Odontogenic Tissues



- Sialolith

