

Large Mixed Lucent/Opaque Lesions

Ossifying Fibroma

Psammomatoid Ossifying Fibroma

Active Juvenile Ossifying Fibroma

Gigantiform Cementoma

Ameloblastic Fibro-odontoma

Odontoameloblastoma

Calcifying Epithelial Odontogenic Tumor

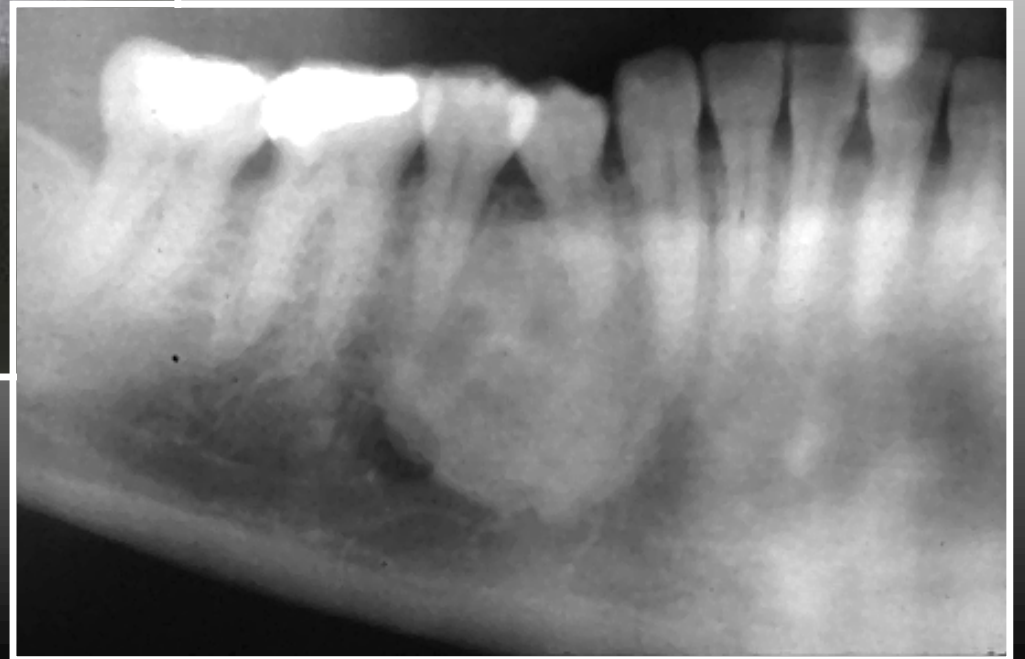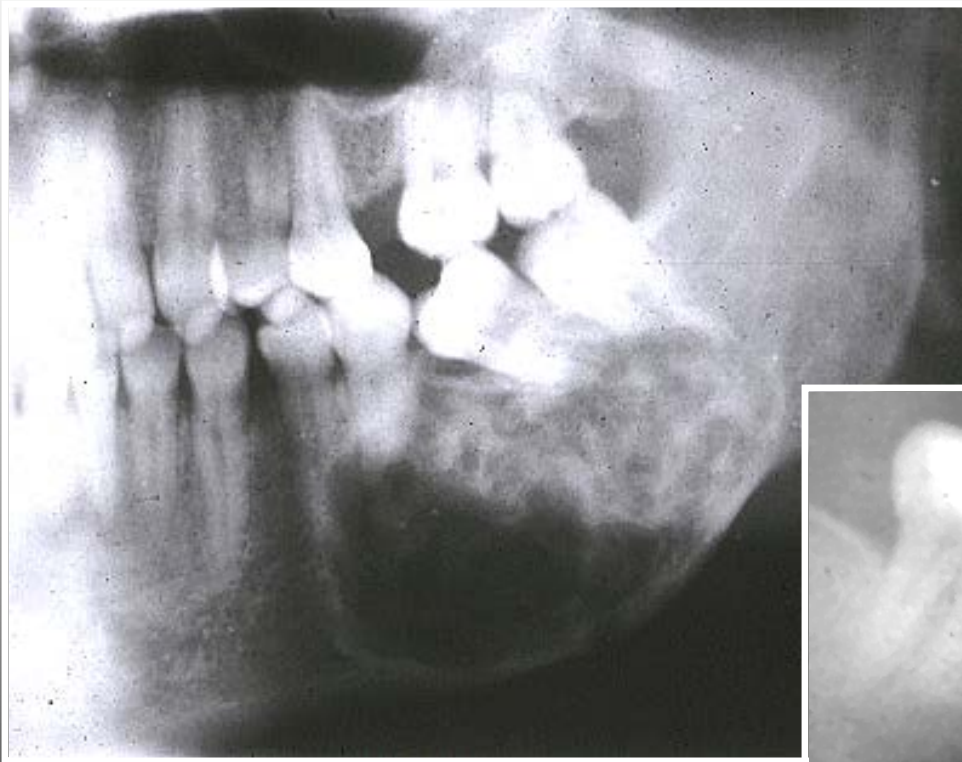
Osteosarcoma

Chondrosarcoma

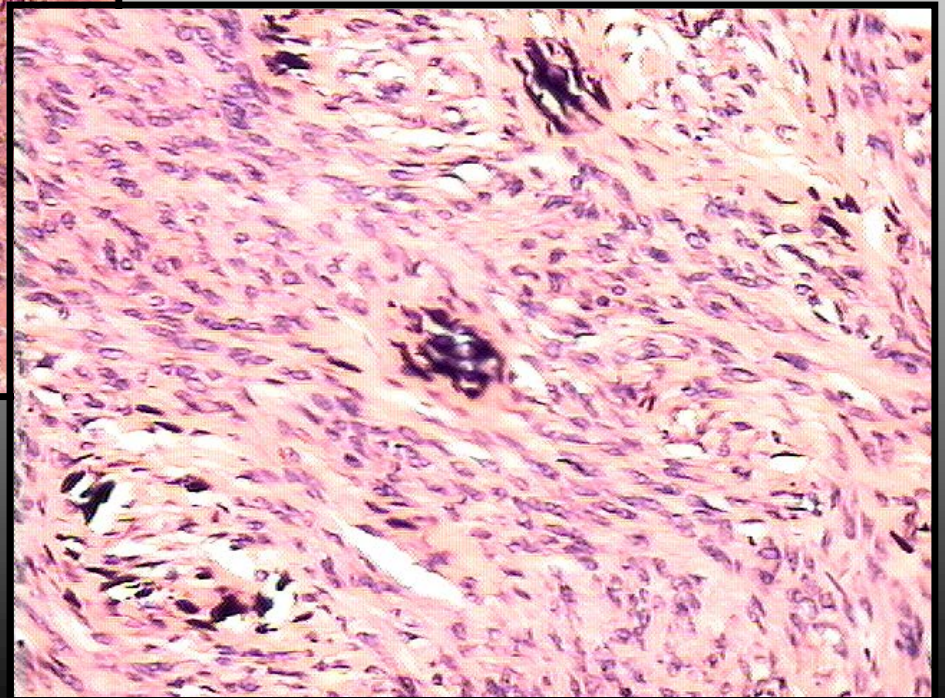
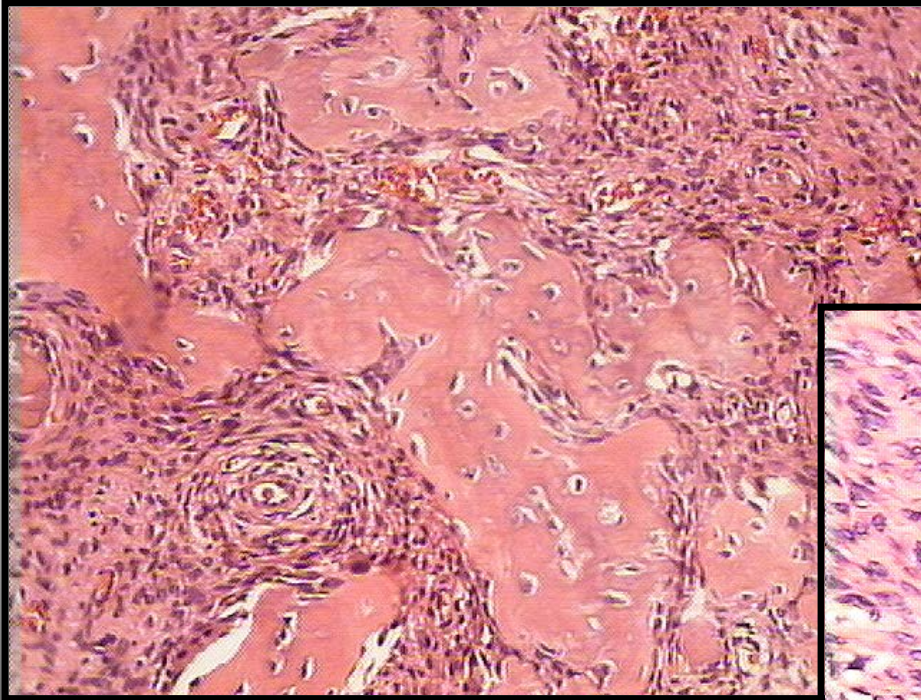
Ossifying Fibroma

- Young Adults
- Body/Posterior Mandible
- Expansile
- Well Demarcated
- Ossifying, Cementifying, Psammomatous
- Curettage/Enucleation
- Juvenile Aggressive OF

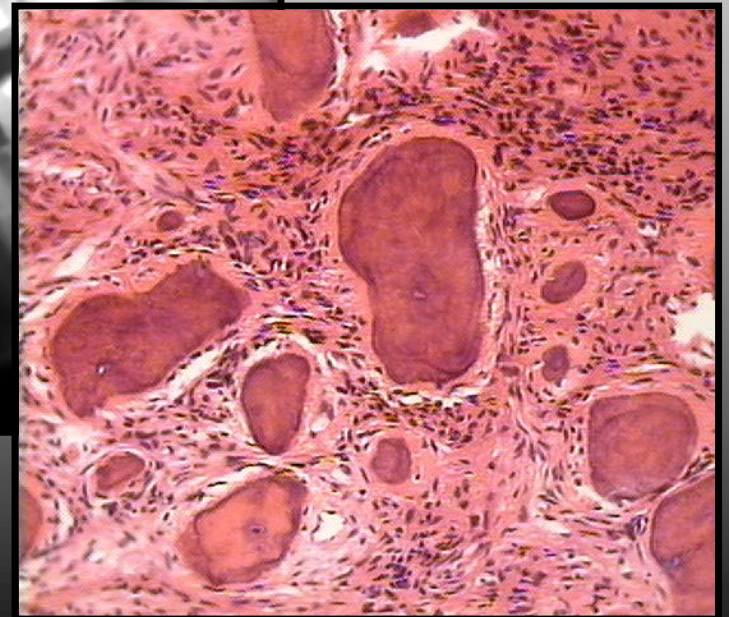
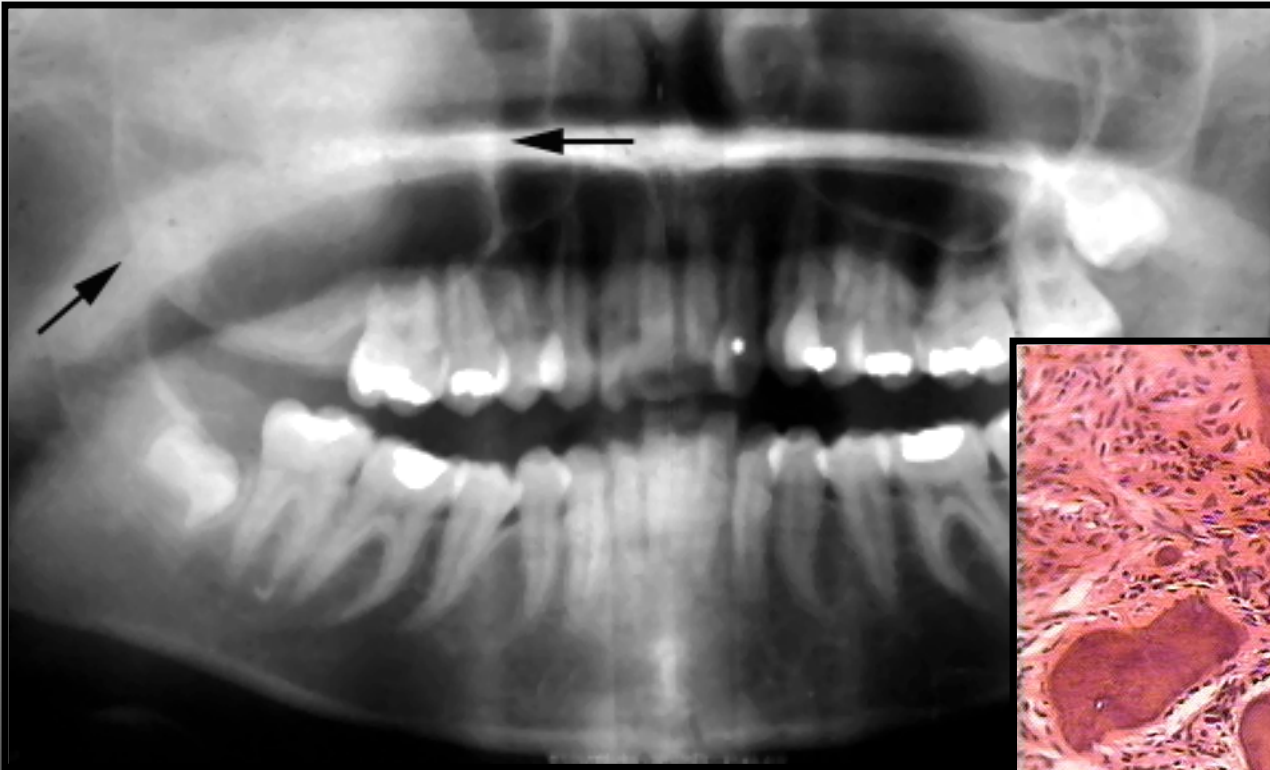
Ossifying Fibroma



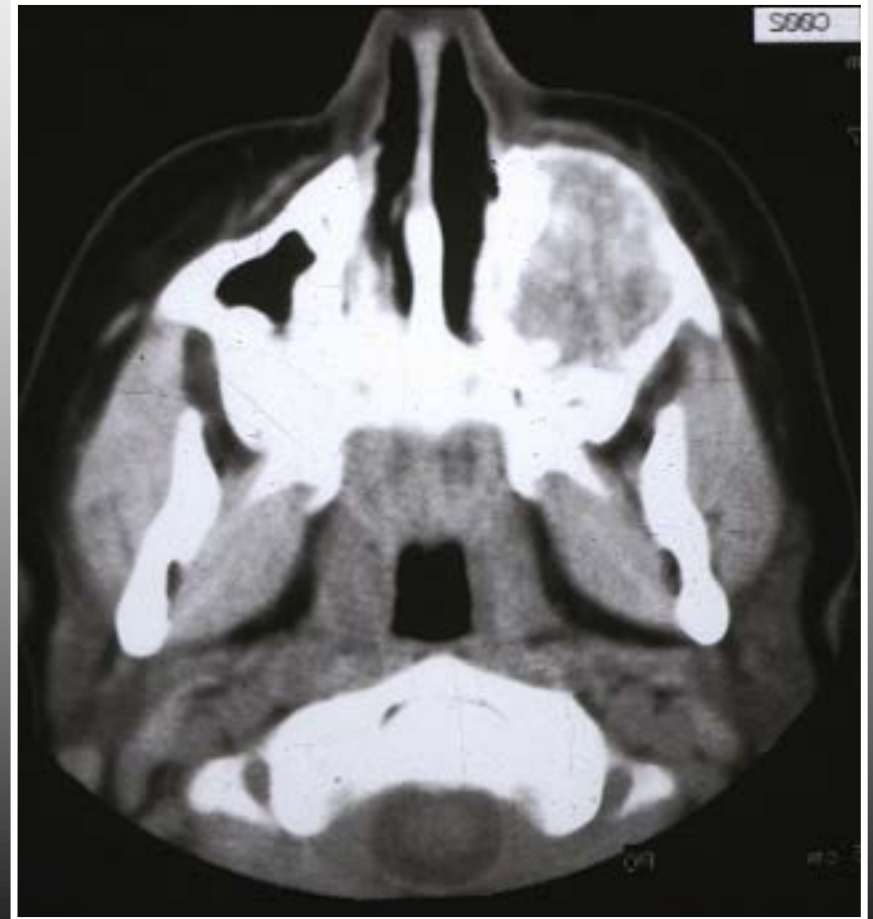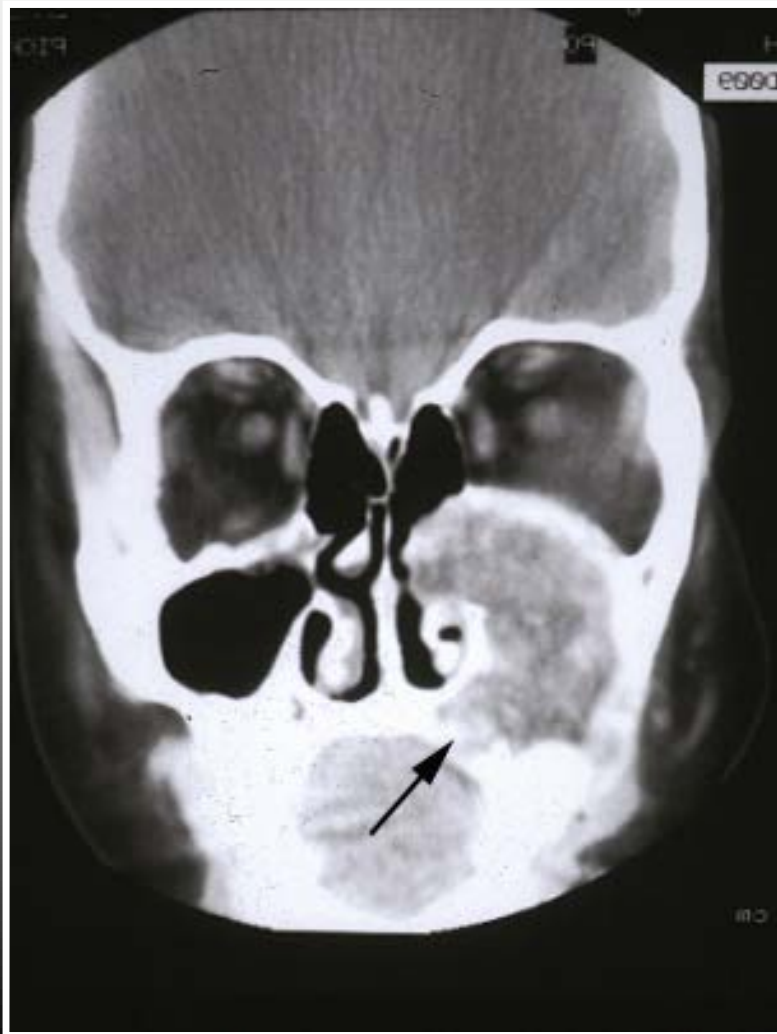
Ossifying Fibroma



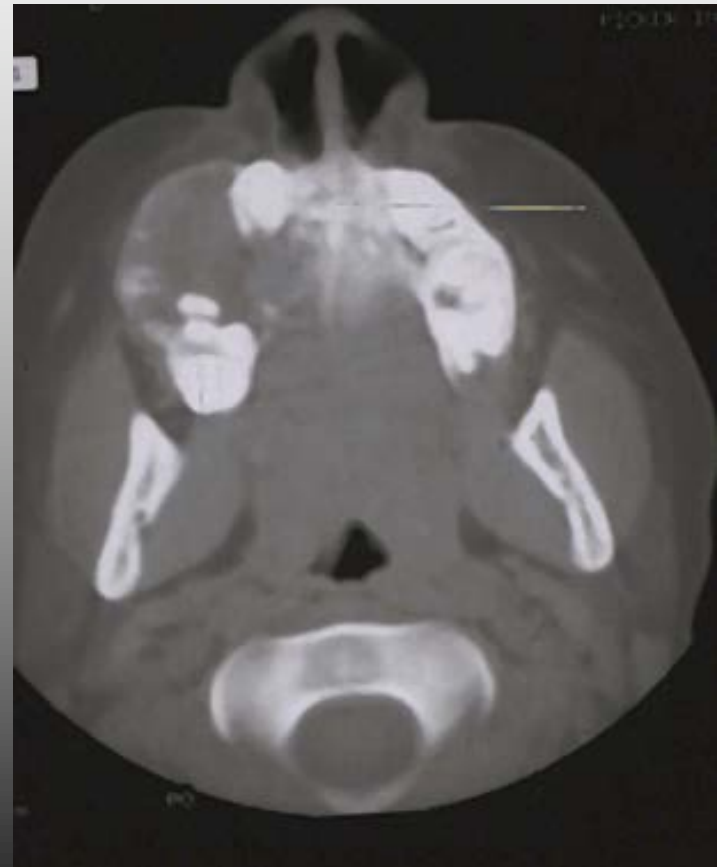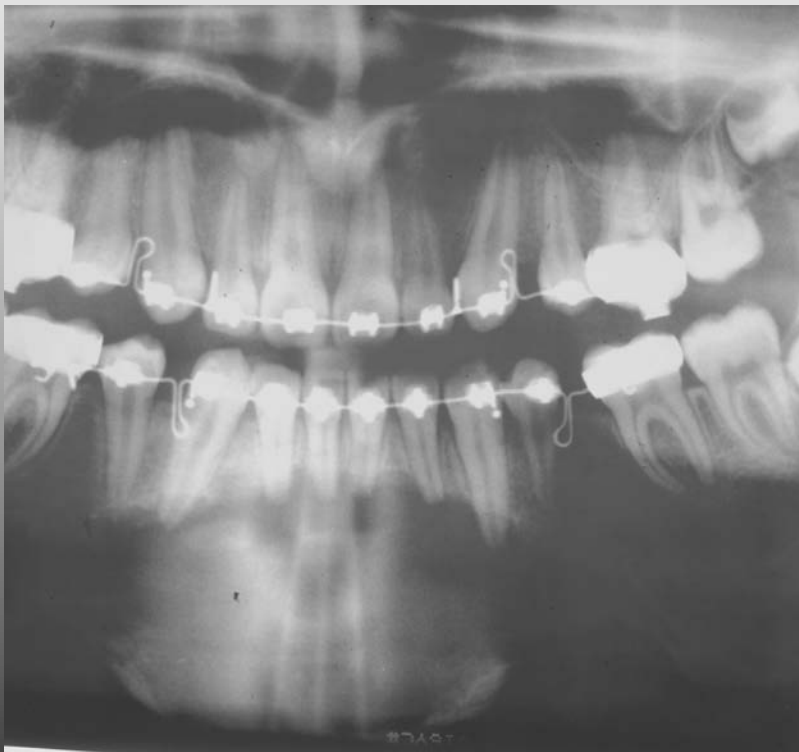Psammomatoid Ossifying Fibroma



Active Juvenile Ossifying Fibroma



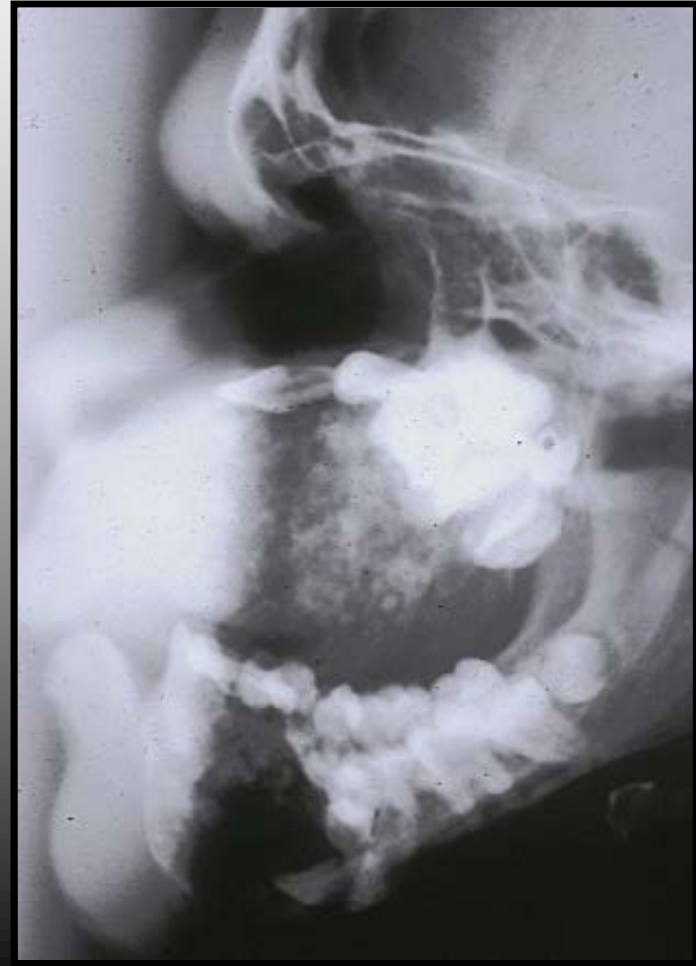
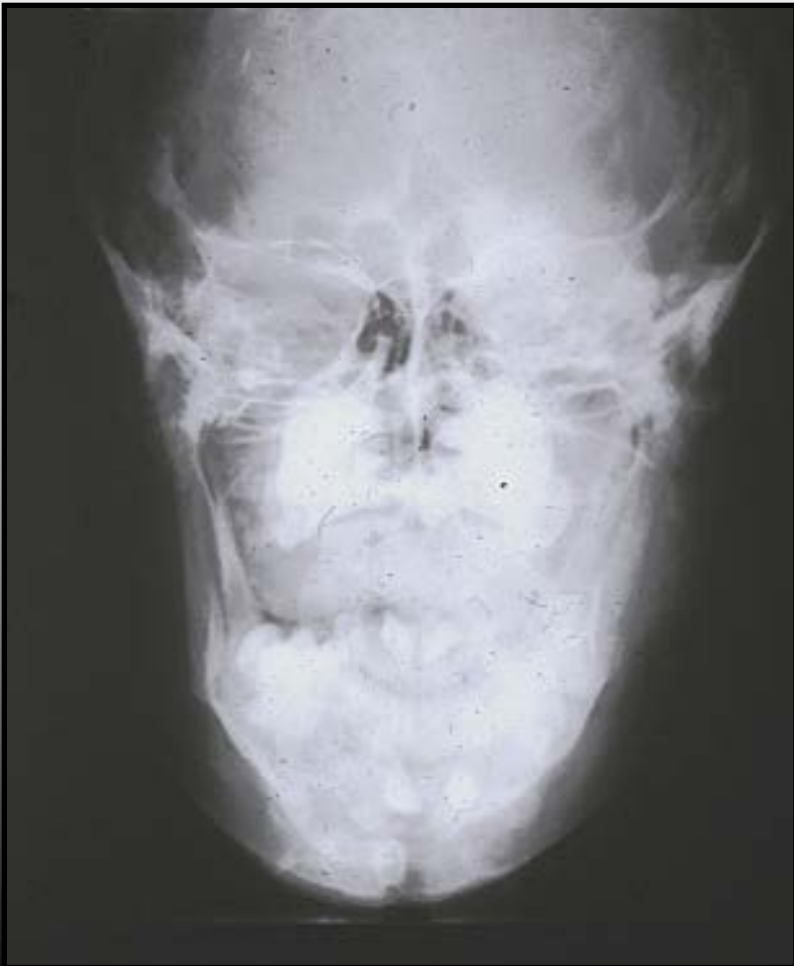Active Juvenile Ossifying Fibroma (Trabecular type)



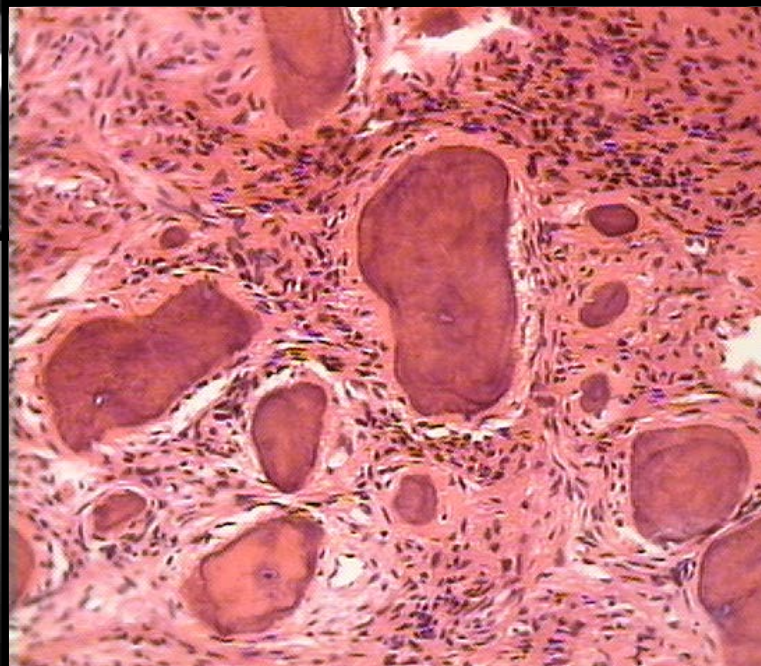
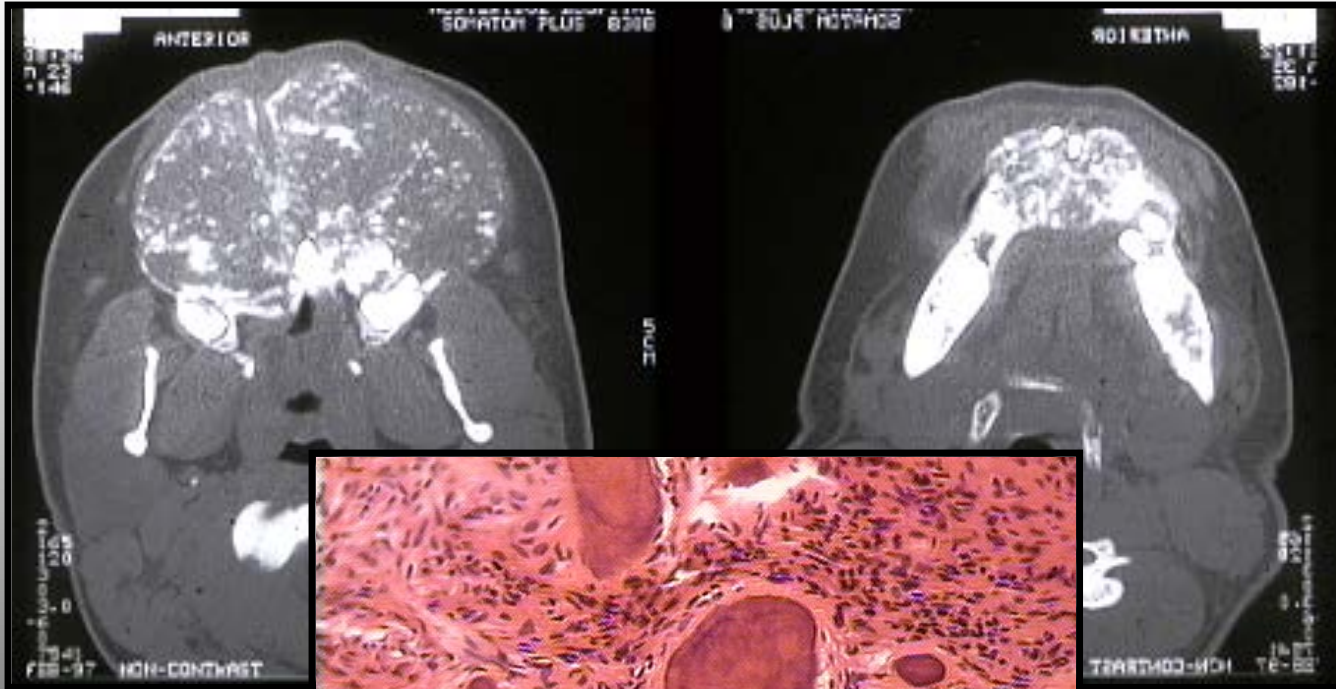
Gigantiform Cementoma

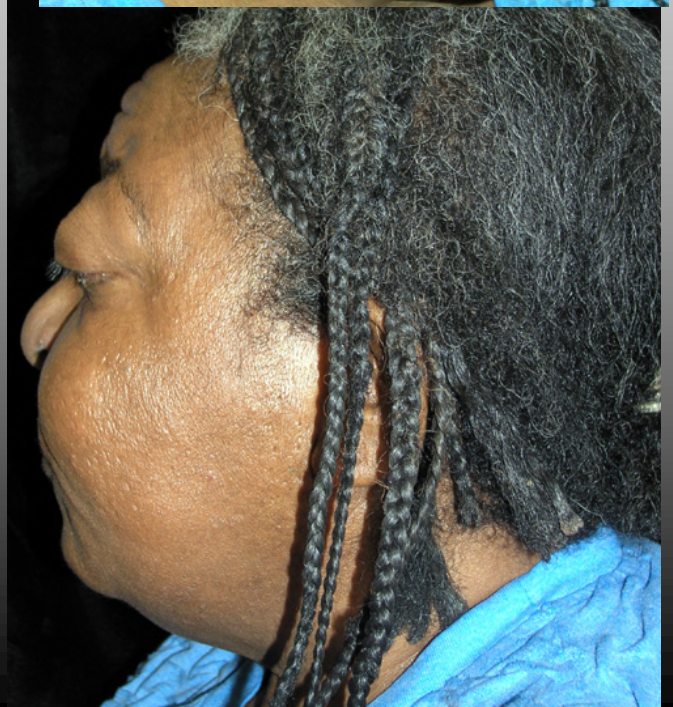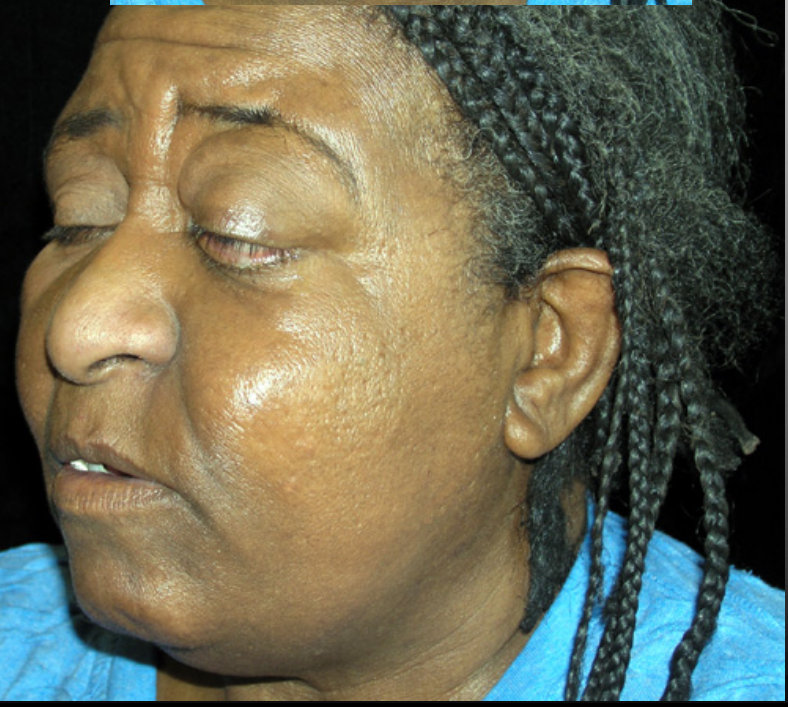
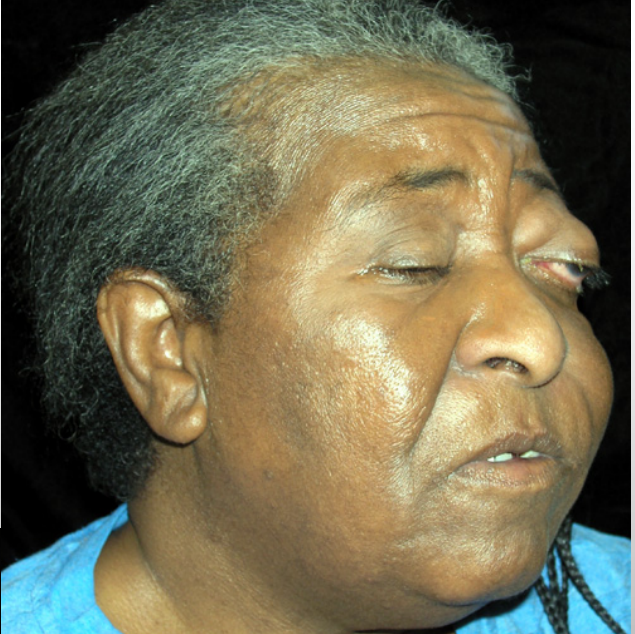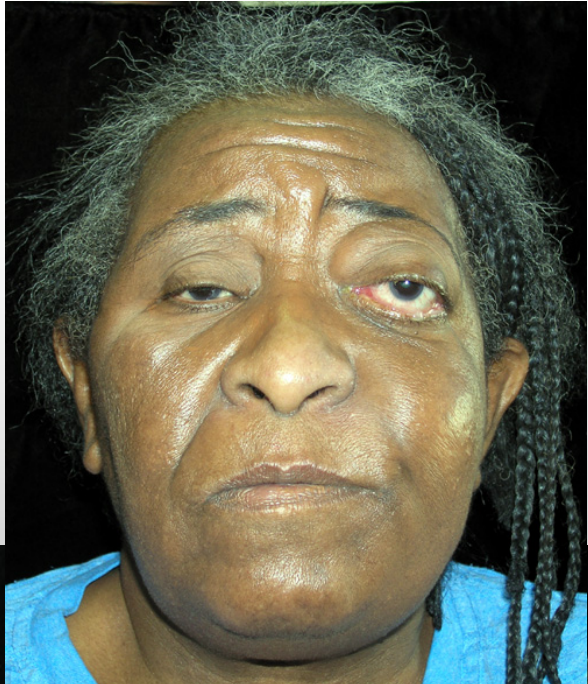- Variant of Ossifying Fibroma
- Childhood Onset
- Often Hereditary
- Variable Expressivity
- Multifocal Massive Lesions
- Bilateral, Both Jaws
- Surgical Contouring/Resection

Gigantiform Cementoma



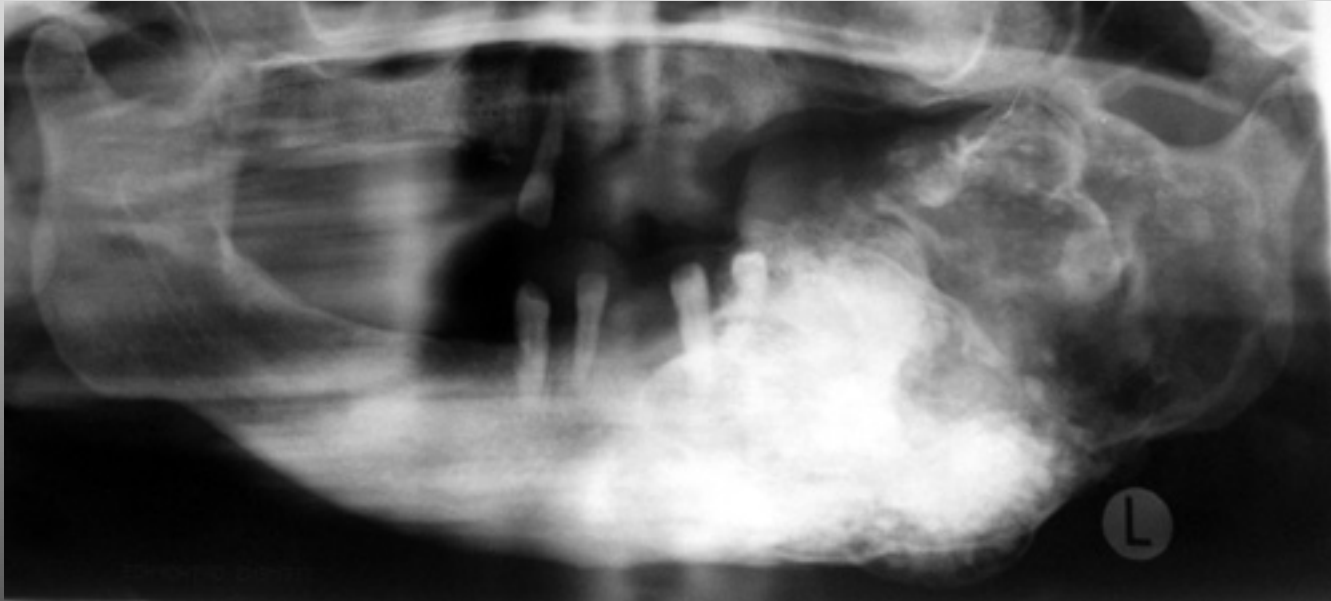
Gigantiform Cementoma



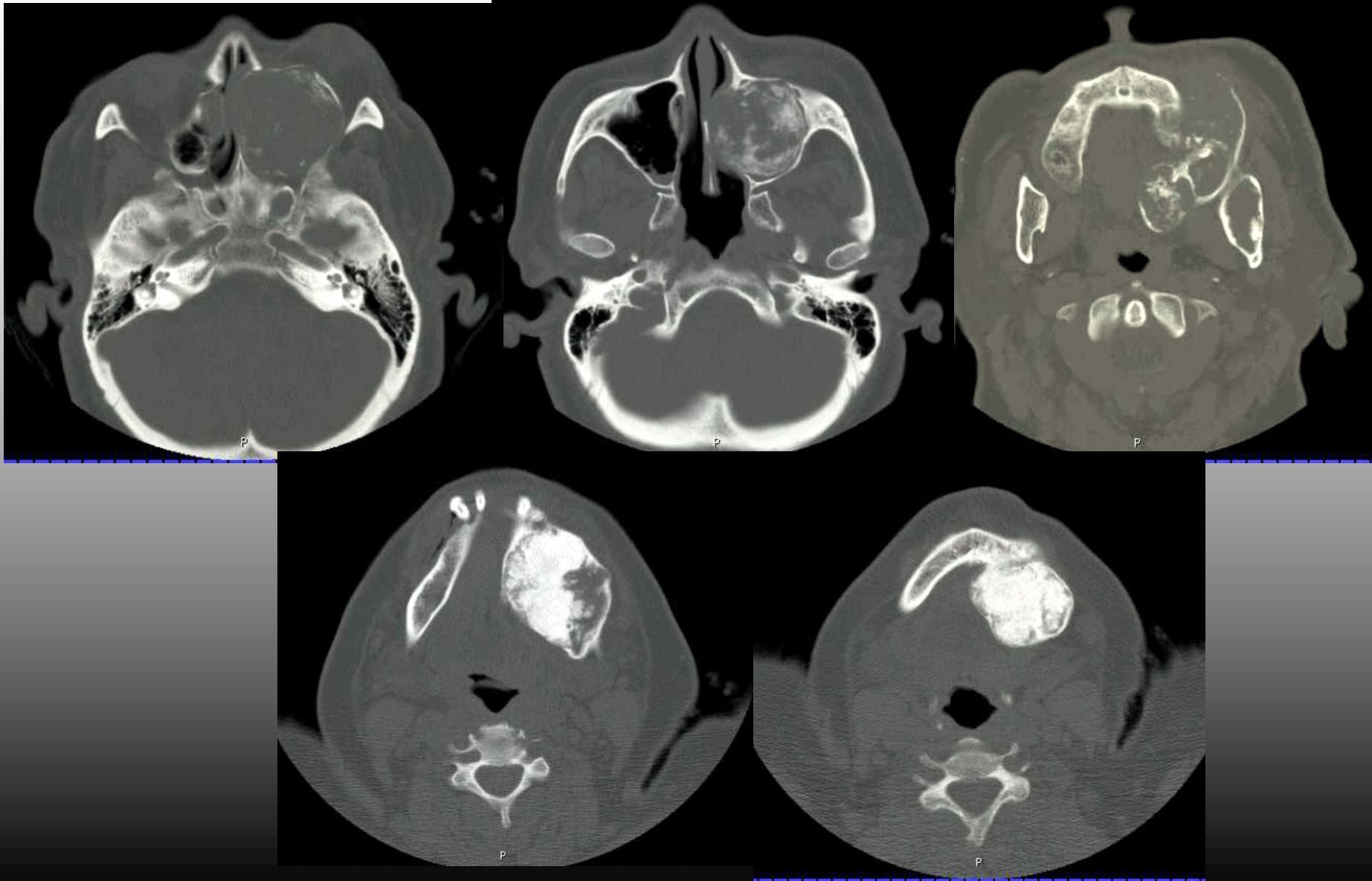


Gigantiform Cementoma

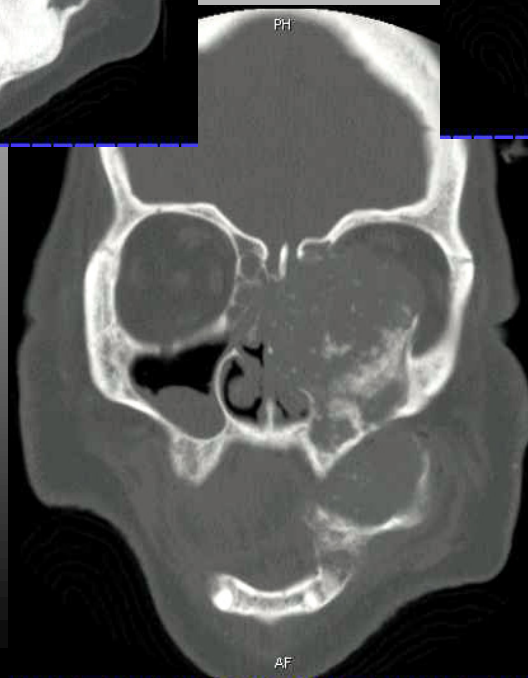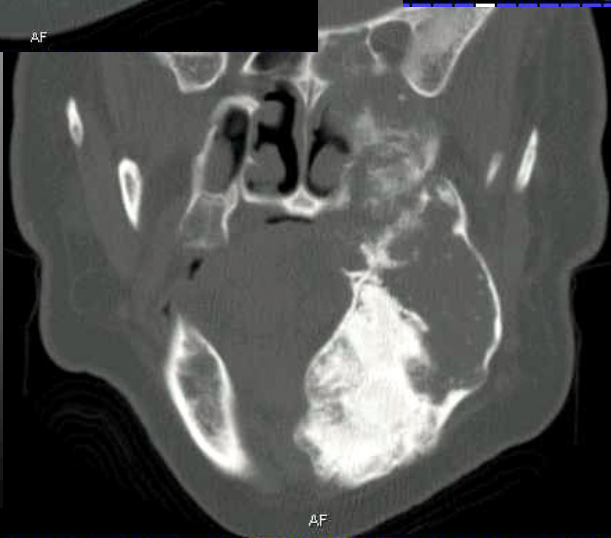
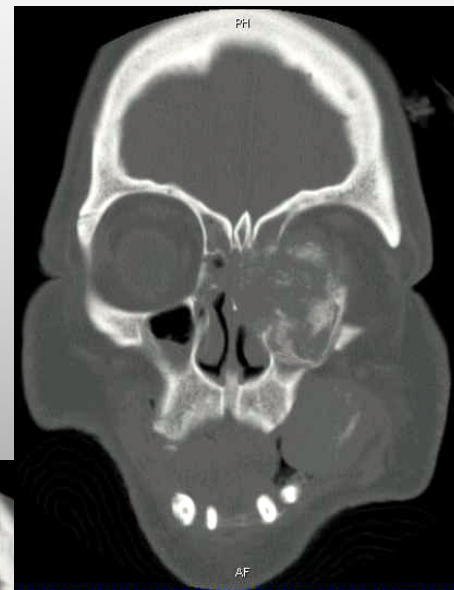
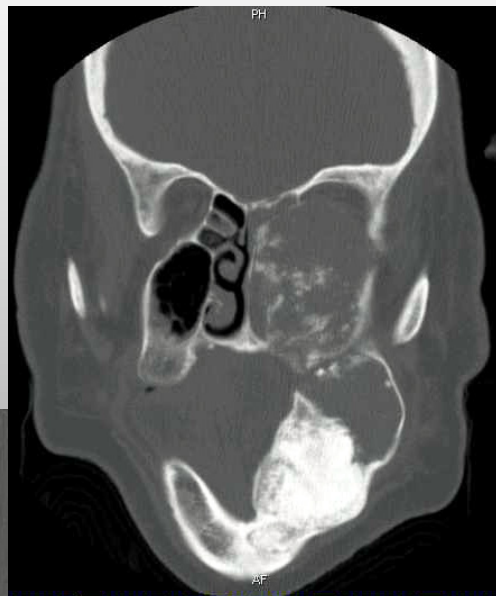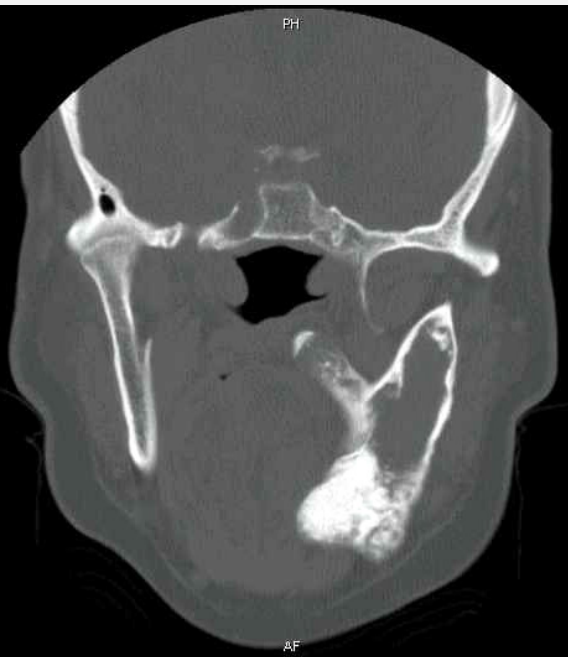
Dr. Tom Indresano
UOP/Highland Hospital OMFS



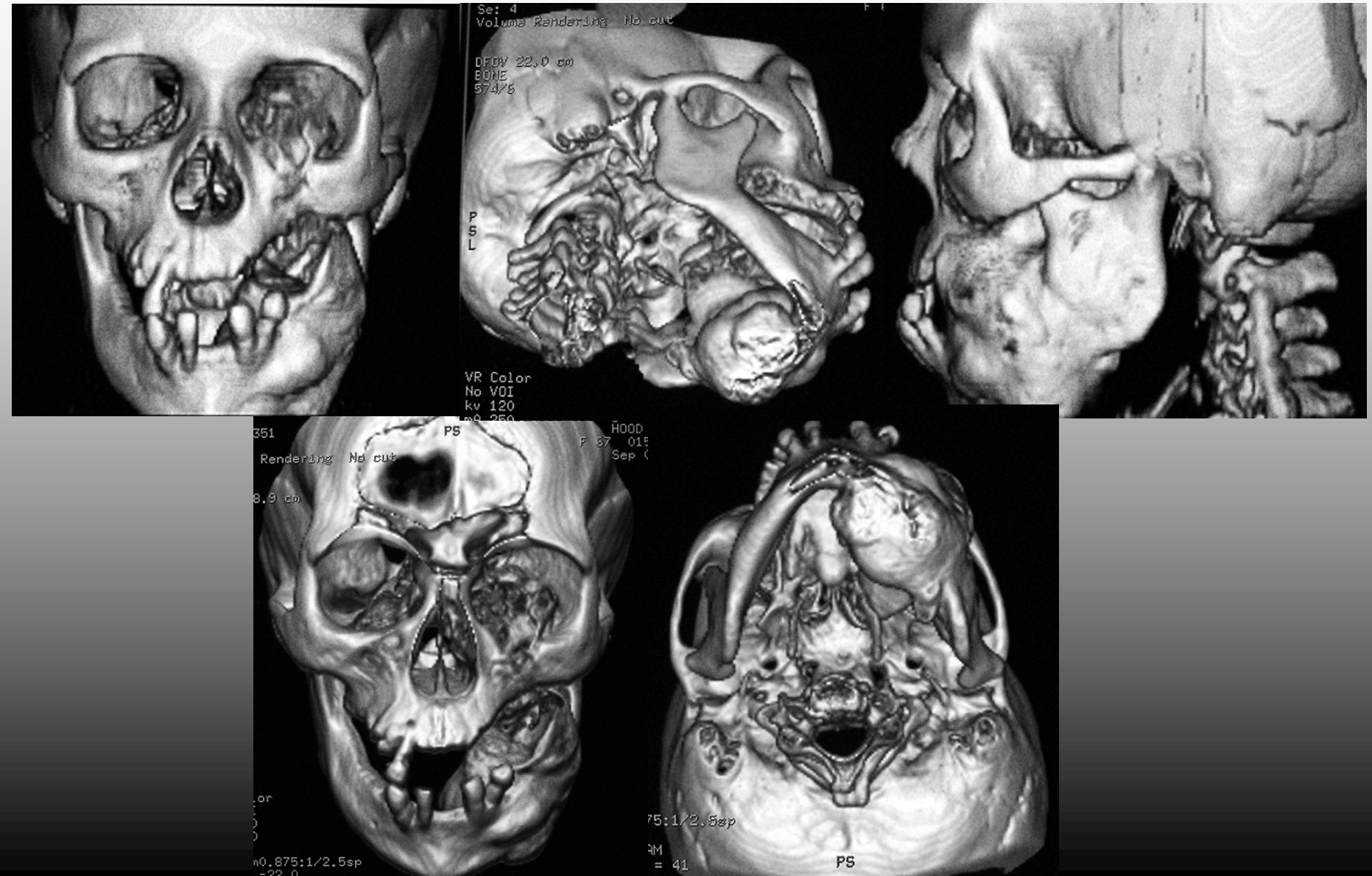Gigantiform Cementoma



Gigantiform Cementoma



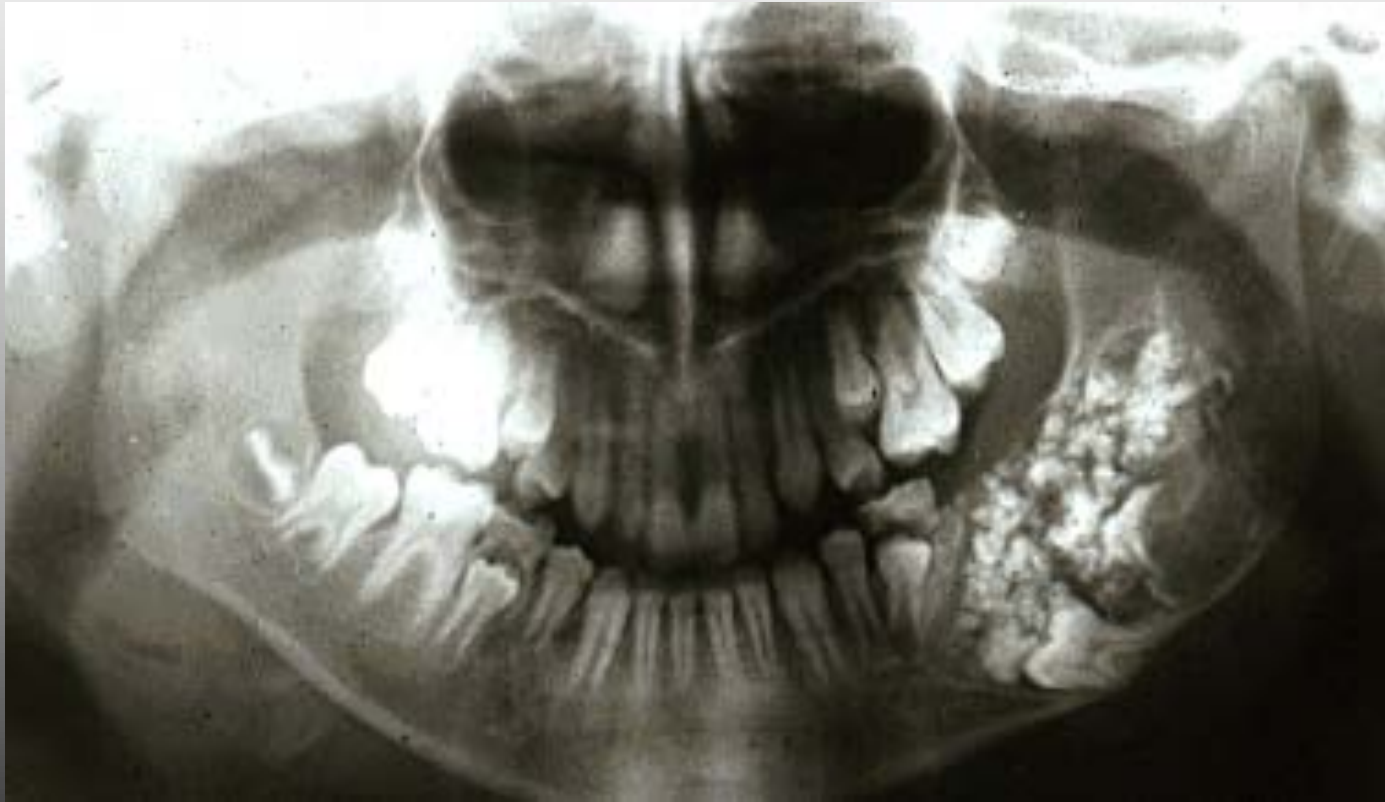
Gigantiform Cementoma



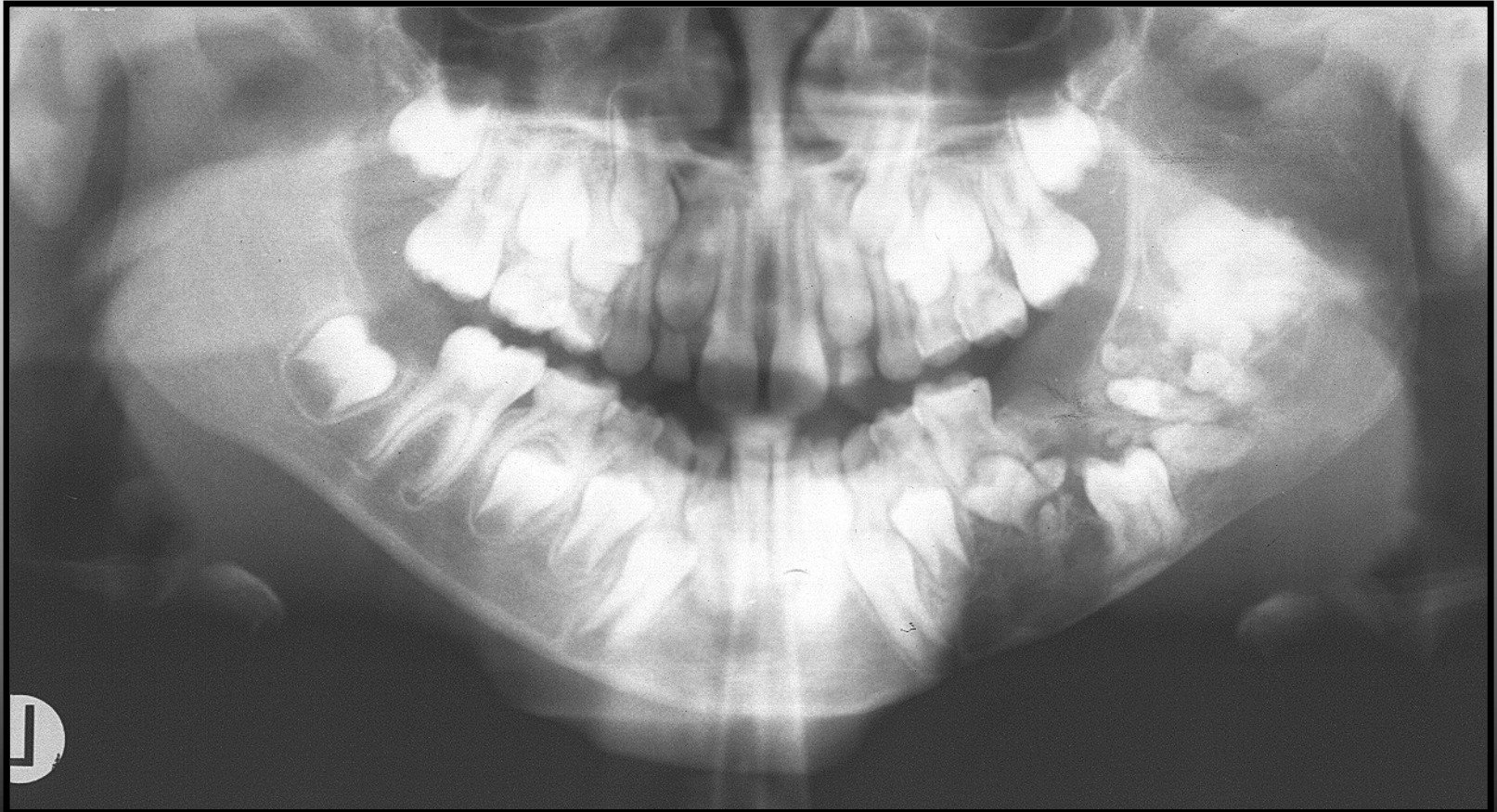
Ameloblastic Fibro-odontoma

- Childhood onset
- Large Tumor
- Expansile
- Multiple Toothlike Structures
- Well Delineated
- Ameloblastic Fibroma with Odontoma
- Enucleation

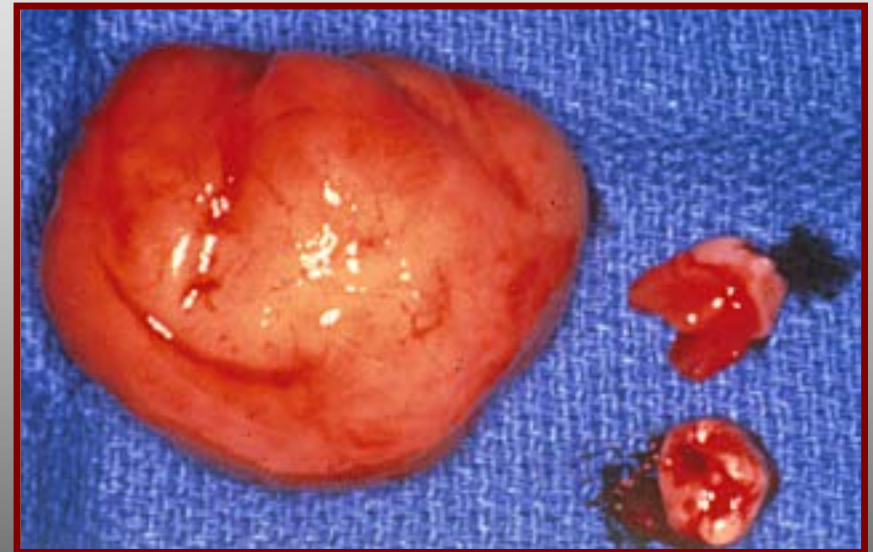
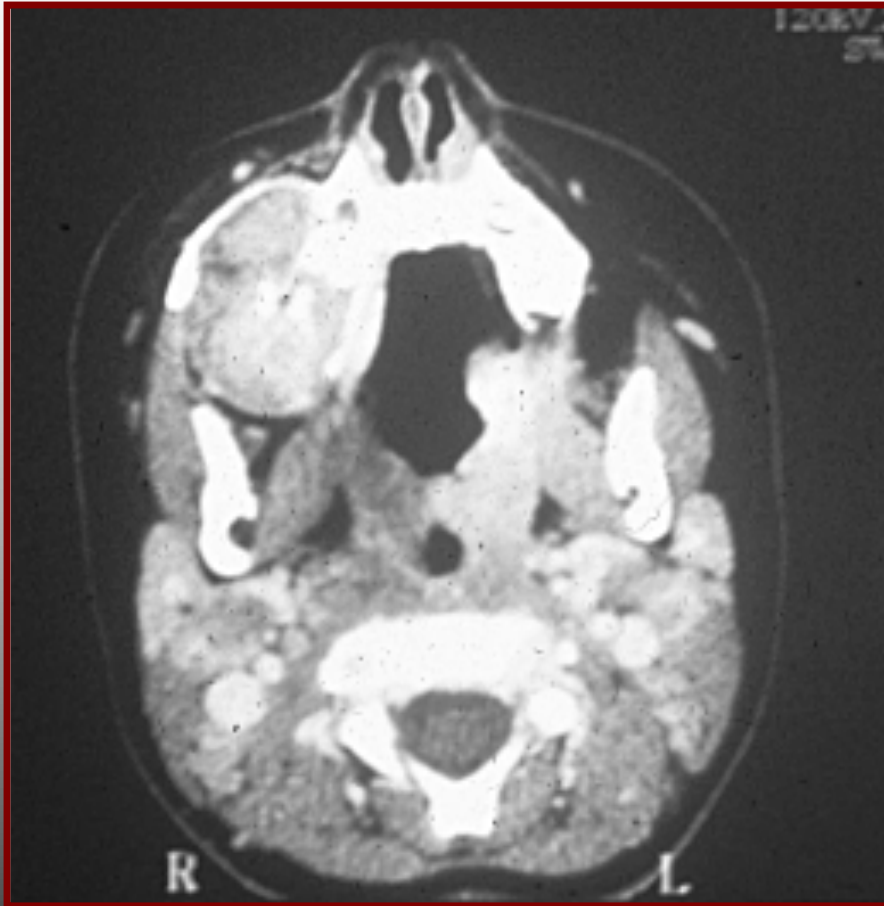Ameloblastic Fibro-odontoma



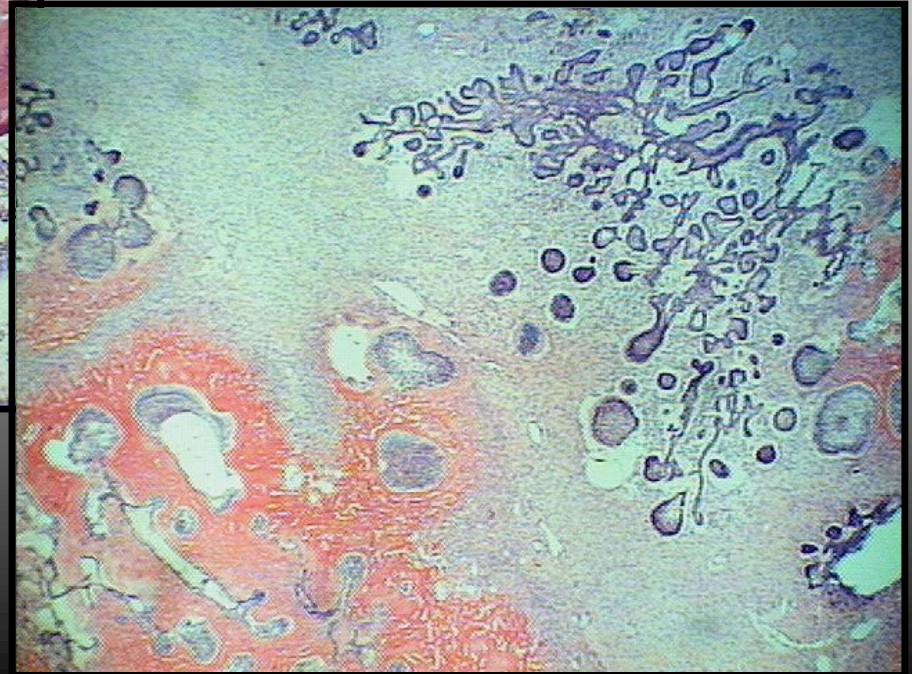
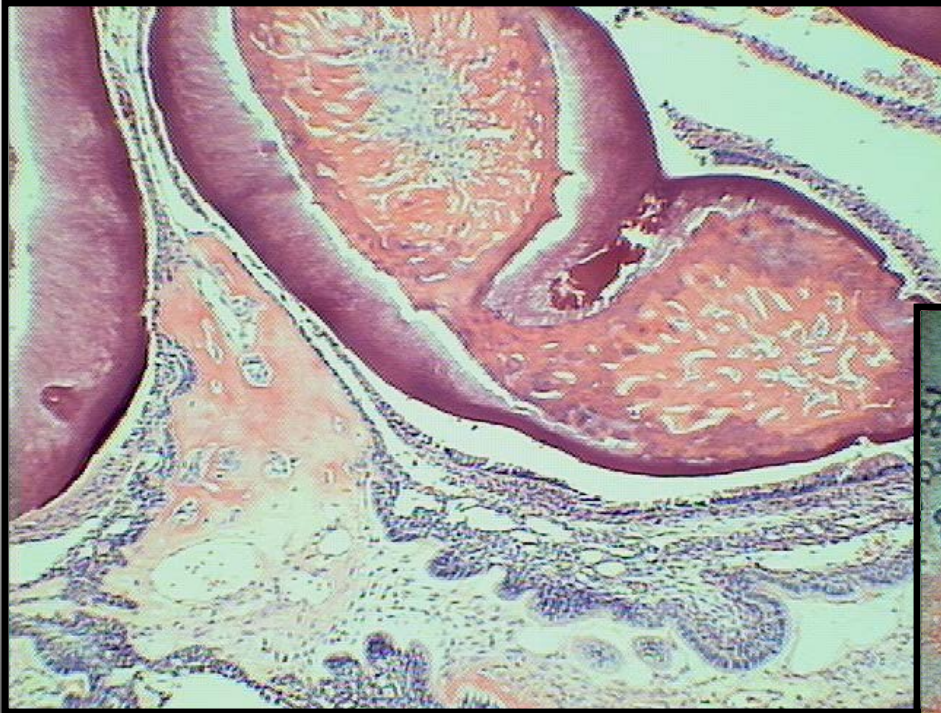Ameloblastic Fibro-Odontoma



Ameloblastic fibro-odontoma



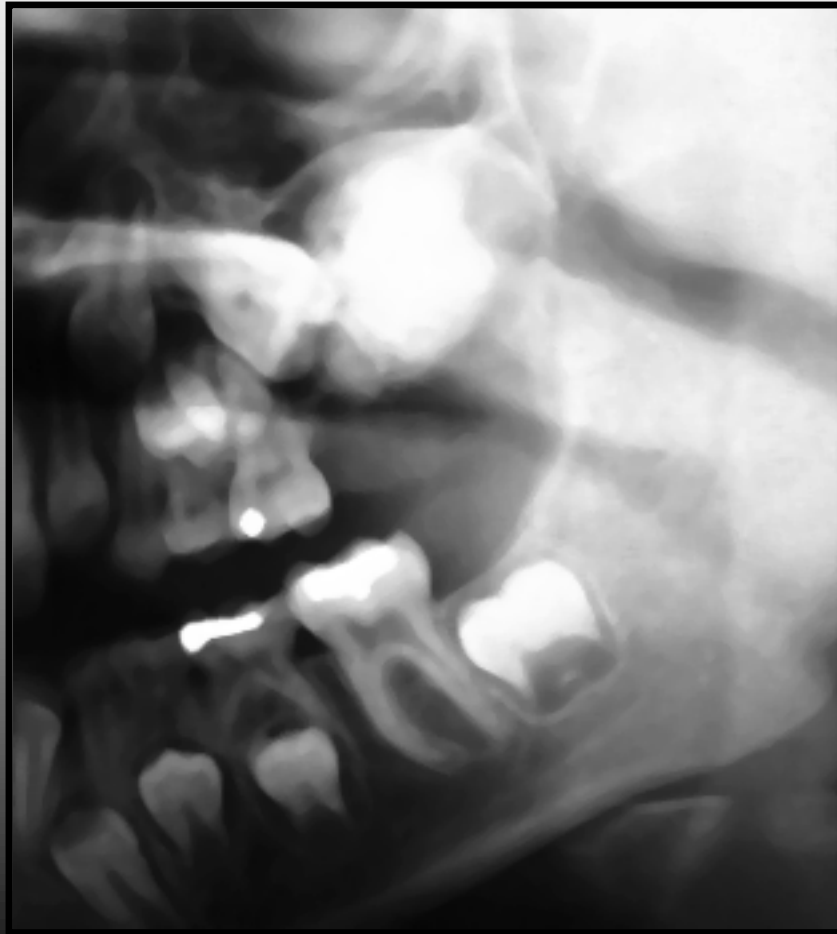
Ameloblastic Fibro-odontoma



Odontoameloblastoma

- Childhood Onset
- Large Tumor
- Expansile
- Multiple Toothlike Structures
- Well Delineated
- Odontoma with Ameloblastoma
- Enucleation/Resection

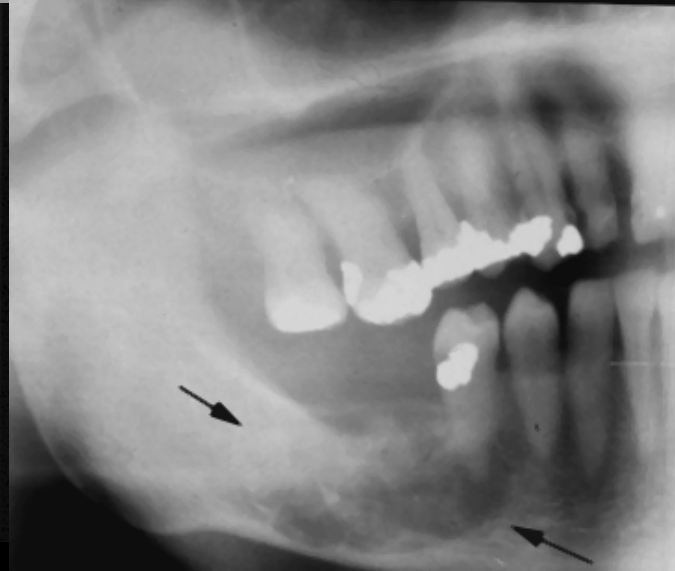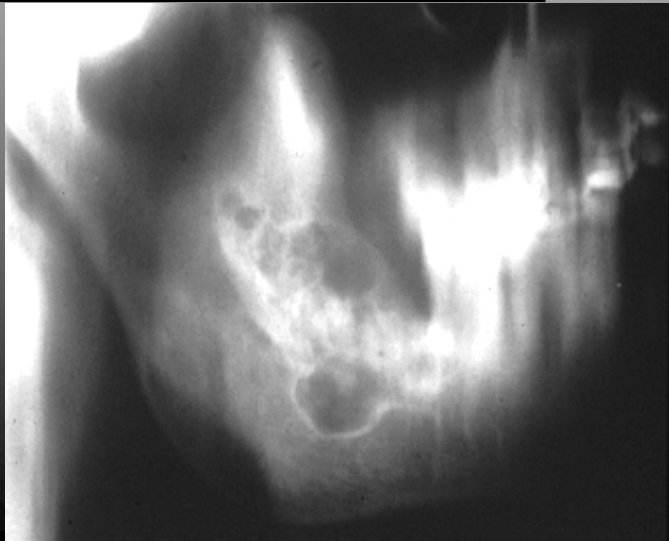
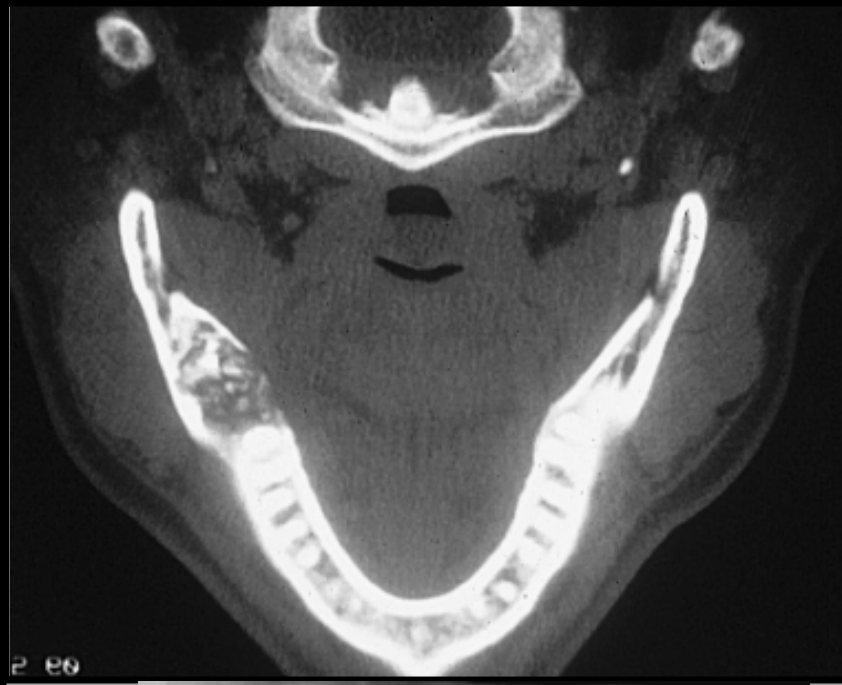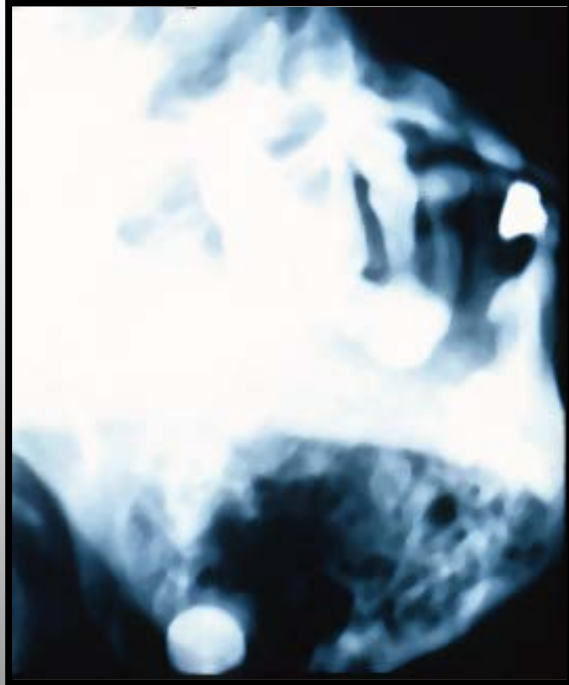Odontoameloblastoma



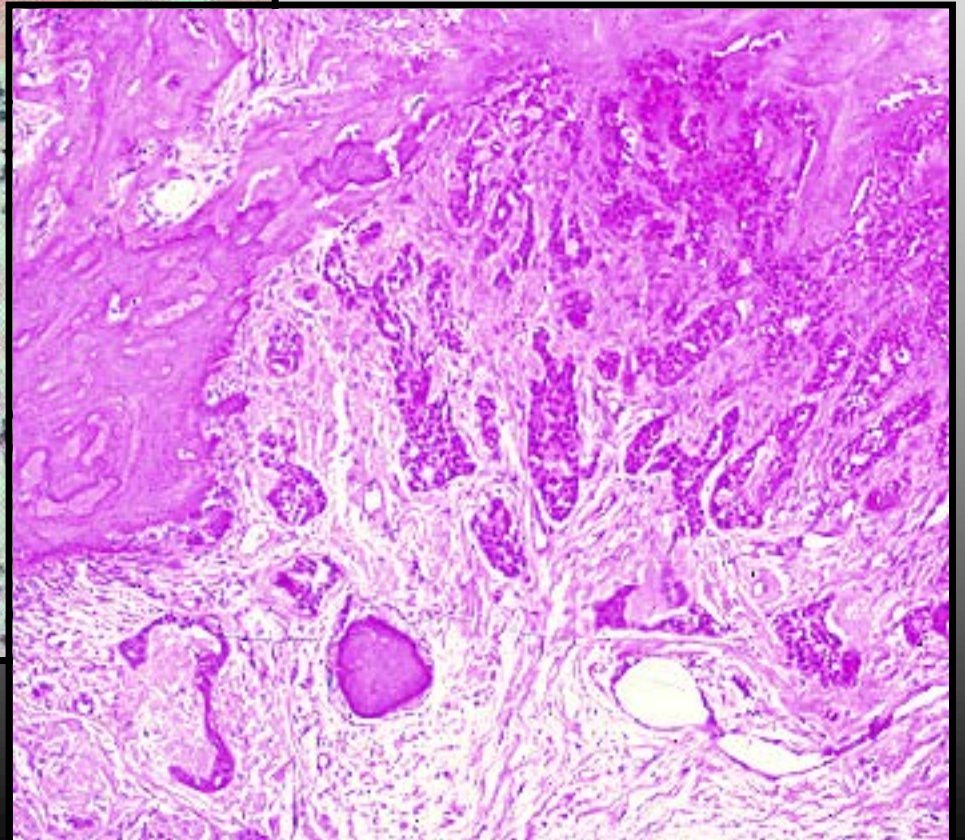
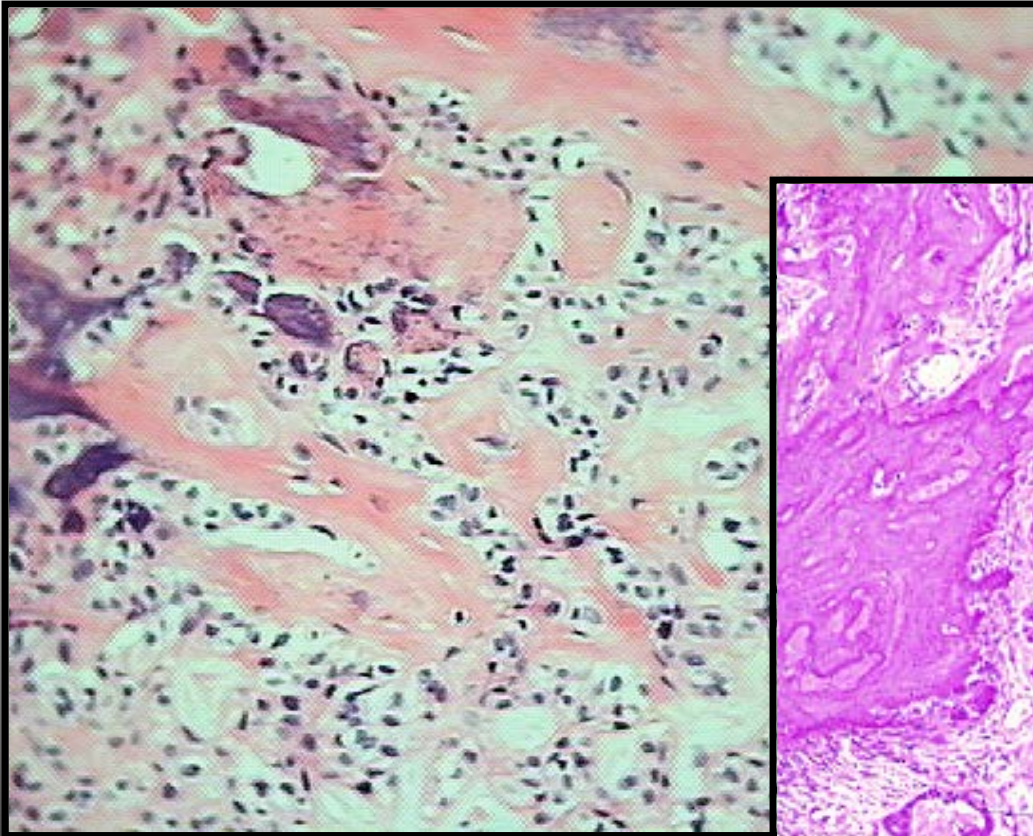
Calcifying Epithelial Odontogenic Tumor

- Adults
- Expansile
- Nontoothlike opacities
- Ill-defined borders
- Amyloid + (Congo Red)
- Resection

Calcifying Epithelial Odontogenic Tumor



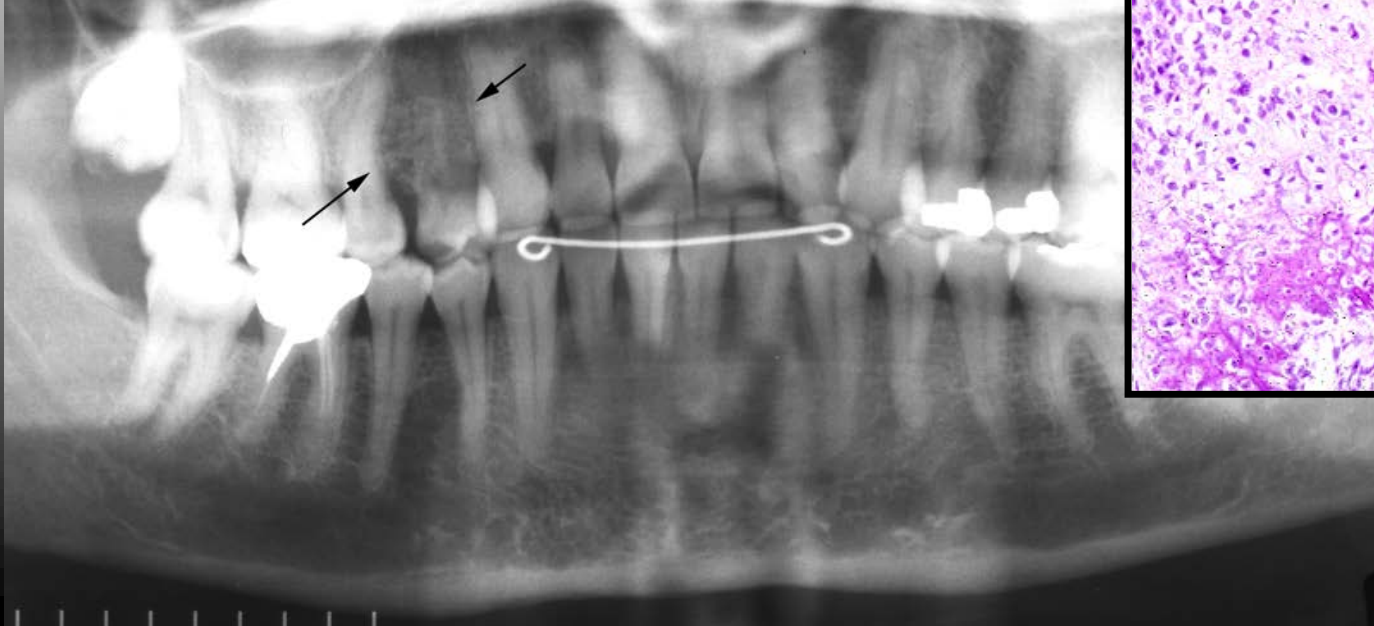
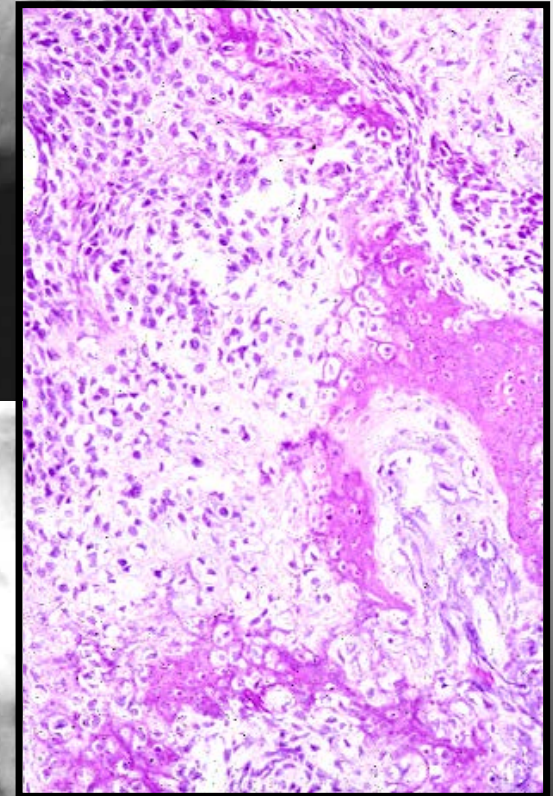
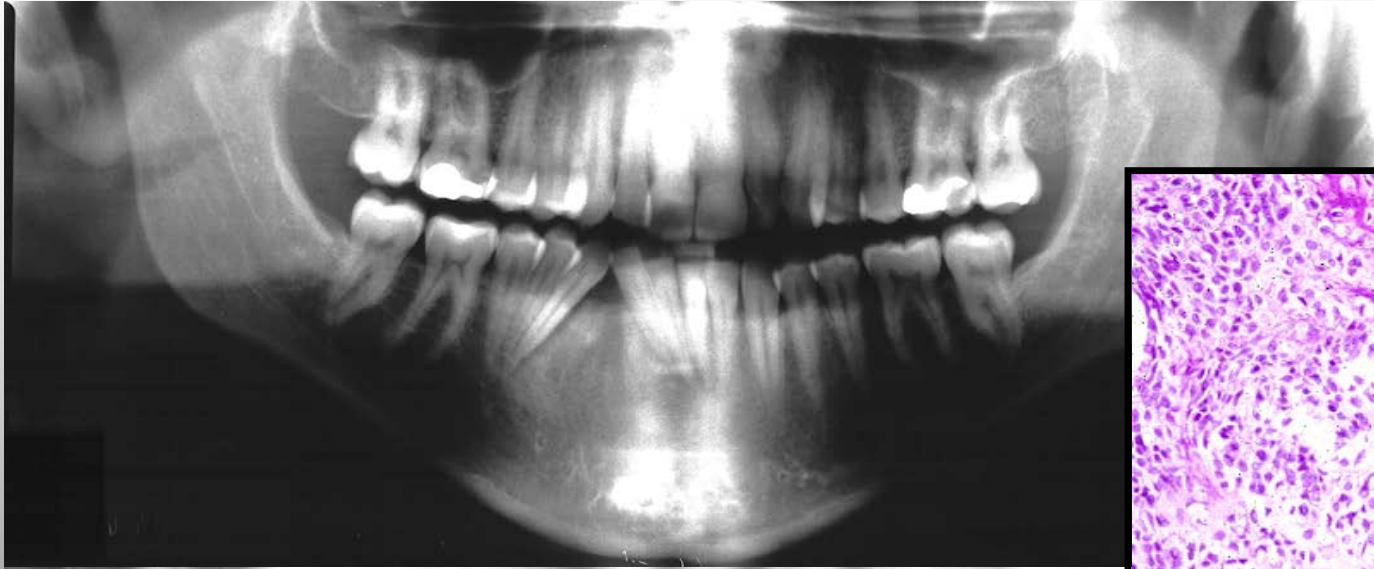
CEOT



Osteosarcoma

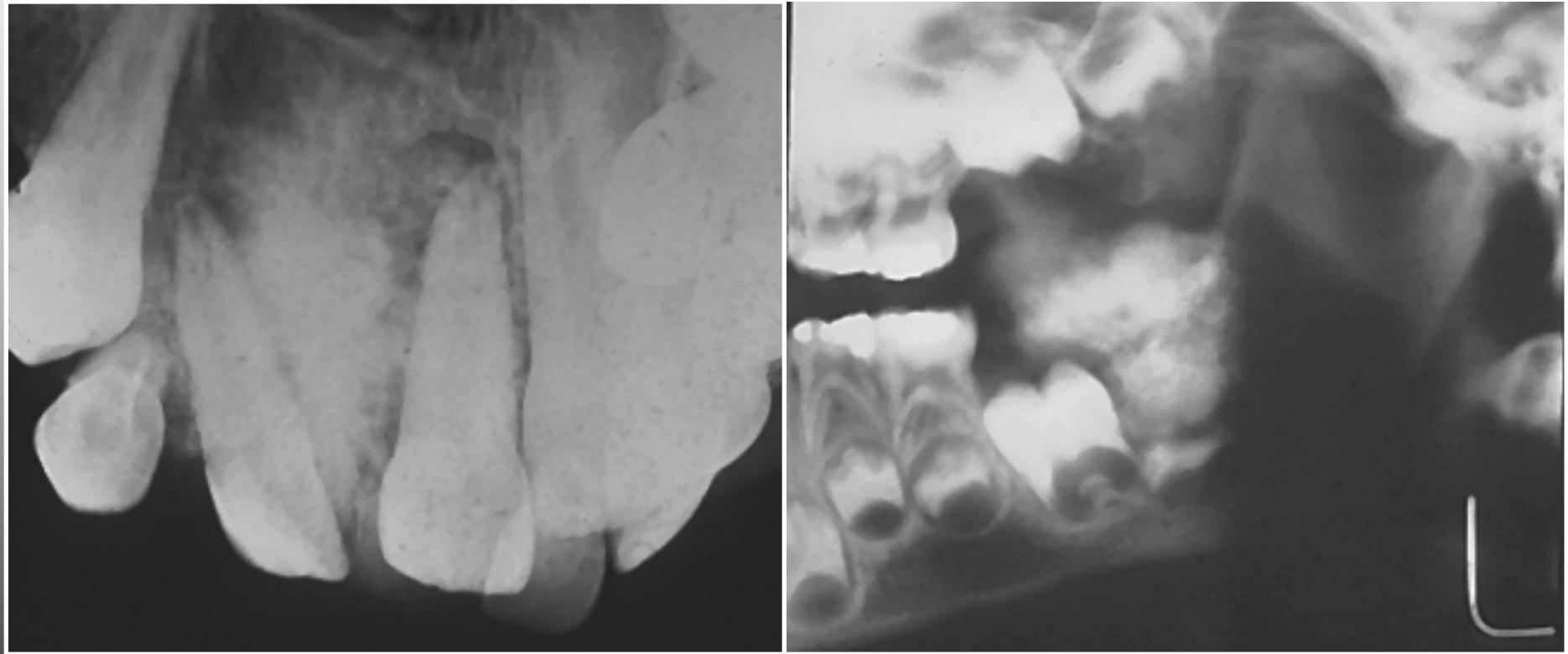
- Young Adults-Elderly
- Mandible>Maxilla
- Ill-defined, Expansile
- Widened PDL
- Sun burst pattern
- Histologic Variants
 - Osteoblastic, Fibroblastic, Chondroblastic
 - Parosteal, Juxtacortical
- Nodal and Distant Mets
- Resection, Radiation

Osteogenic Sarcoma



Osteogenic Sarcoma

Sun Burst Patterns



Chondrosarcoma

- Young Adults-Elderly
- Mandible>Maxilla
- Ill-defined, Expansile
- Histologic Variants
 - Well Differentiated
 - Myxoid
 - Mesenchymal
- Nodal and Distant Mets
- Resection, Radiation

Chondrosarcoma

